



## MEDICAL CERTIFICATE

Please attach all test results in English, based on this report is filled.

### PERSONAL DETAILS

[These should exactly be the same as they appear in the applicant's/student's passport]

First / given name(s):

Rahul

Family name(s) / surname(s):

Amanakuttan

Permanent home address:

176.A, KRWA, Manjadimoodu, Vattiyookavu, Trivandrum

Date of birth (DOB): (dd/mm/yyyy):

12/12/2003

Place of birth (city, province, country):

Bhopal, Madhya Pradesh, India.

### PAST MEDICAL HISTORY

Previous diseases of the applicant/student:

Nil

Chronic diseases, pre-existing conditions known:

Nil

Detailed medications:

Nil

Allergies:

Nil

Remarks / Special recommendations / Special needs:

Nil



**VACCINATIONS** (with exact times of the immunization given):

(If the patient is not vaccinated, please consider vaccination before arriving in Hungary)

Morbilli (measles)

Pertussis (whooping cough)

Poliomyelitis

Hepatitis B

Typhoid fever

**SEROLOGICAL TESTS** (time of testing and titer within 12 months):

Morbilli antibody (IgG) titer

if its negative/equivocal, a booster dose of MMR vaccine should be administered

HIV

Non reactive

Syphilis

Non reactive

HBsAg

Anti-HCV

Non reactive

**BLOOD TESTS** (time of testing and result within 12 months):

Blood count

✓ Normal / Abnormal

Fasting blood glucose

✓ Normal / Abnormal

Liver transaminases (AST-GOT, ALT-GPT)

✓ Normal / Abnormal

Kidney function (BUN, creatinine, GFR)

✓ Normal / Abnormal

Please attach the results.

**URINE TEST** (time of testing and result within 12 months):

✓ Normal / Abnormal

Please attach the results.



**TUBERCULOSIS** (X-ray report or Quantiferon (IGRA) blood test within 12 month):

Negative / Positive

Chest X-ray - Normal

Please attach the results.

**DOCTOR'S STATEMENT**

I, the undersigned Dr. Sukesh R.S (Doctor of Medicine; registration number: TCMC 29935;  
phone number: 0471-234443), after examining the applicant/student hereby certify under penalty of perjury  
that the foregoing is true and correct to the best of my knowledge.

PLACE AND DATE:

Trivandrum  
12/06/2024

Dr. SUKESH. R. S MBBS, MD, C.Diab  
Reg. No. 29935  
Consultant Physician & Diabetologist  
DOCTORS' SIGNATURE AND STAMP  
Killipalam, Trivandrum-02


Take note, University of Debrecen reserves the right to check the validity of any of the results and may order retesting for any of the laboratories or conditions above, which may lead to further action.

Patient No	: 0001037018	Invoice No.	: 015271
Name	: MR.RAHUL OMANAKUTTAN	Invoice Date	: 11/06/2024 12:08:21 PM
Gender/ Age	: Male / 20 Yrs-5 Mths-30 Days	Sample Date	: 11/06/2024 01:10:07 PM
Sample #	: 12339941	Referred By	: Dr.SUKESH R S
Result Verified	: 11/06/2024 02:32:21 PM	Dept./Unit	: GENERAL MEDICINE

## LABORATORY REPORT HAEMATOLOGY

Test Name	Result	Ref. Range	Units	Method	Sample
<b>CBC</b>					
WBC COUNT	5710	5000 - 10000	Cells/Cumm	FLUORESCENT FLOWCYTOMETRY	BLOOD
RBC COUNT	4.76	4.50 - 6.50	million/cm	DC DETECTION	BLOOD
HB	13.5	13.0 - 18.0	gm/dL	PHOTOMETRY	BLOOD
HEMATOCRIT	<b>41.9</b>	42.0 - 52.0	%	CALCULATED	BLOOD
MCV	88.0	76.0 - 96.0	fl	CALCULATED	BLOOD
MCH	28.4	27.0 - 32.0	pg	CALCULATED	BLOOD
MCHC	32.2	31.0 - 35.0	gm/dL	CALCULATED	BLOOD
PLATELET COUNT	2.61	1.50 - 4.00	Lakhs/Cumm	DC DETECTION	BLOOD
<b>DIFFERENTIAL COUNT</b>					
NEUTROPHILS	66.5	40-75	%	FLUORESCENT FLOWCYTOMETRY	BLOOD
LYMPHOCYTES	28.0	20-45	%	FLUORESCENT FLOWCYTOMETRY	BLOOD
MONOCYTES	3.9	2-10	%	FLUORESCENT FLOWCYTOMETRY	BLOOD
EOSINOPHILS	1.1	<6	%	FLUORESCENT FLOWCYTOMETRY	BLOOD
BASOPHILS	0.5	< 2	%	FLUORESCENT FLOWCYTOMETRY	BLOOD
ESR	14	Male : 0 - 15 Male > 70 Yrs : < 30 Female : 0 - 20 Female > 70 Yrs : < 35	mm/hr	WESTERGREN METHOD	BLOOD


\*\* End Of Report \*\*



DR.ILMA KUNJU MOHAMED  
MBBS,MD (PATHOLOGY)

ENTERED BY

AUTHORIZED BY



Note: Lab tests have their limitations; results need not always correlate with clinical findings. But in the event any doubt, Please ask for a repetition with fresh specimen.

PRINTED TIME : 12/06/2024 09:38 AM

PRINTED BY : LIZY SK

Patient No	: 0001037018	Invoice No.	: 015271
Name	: MR.RAHUL OMANAKUTTAN	Invoice Date	: 11/06/2024 12:08:21 PM
Gender/ Age	: Male / 20 Yrs-5 Mths-30 Days	Sample Date	: 11/06/2024 01:10:07 PM
Sample #	: 12339941	Referred By	: Dr.SUKESH R S
Result Verified	: 11/06/2024 02:32:21 PM	Dept./Unit	: GENERAL MEDICINE

### LABORATORY REPORT BIOCHEMISTRY

Test Name	Result	Ref. Range	Units	Method	Sample
BUN	12.70	7.00 - 18.00	mg/dl	UREASE METHOD	SERUM
CREATININE <i>Measurement Uncertainty is 6%</i>	0.85	0.67 - 1.17	mg/dL	ENZYMATIC	SERUM
FASTING BLOOD SUGAR	90	74 - 106	mg/dL	HEXOKINASE METHOD	SERUM
SGPT/ALT	13.5	<51	IU/L	UV WITH P5P METHOD	SERUM
SGOT/AST	25.4	<51	IU/L	UV WITH P5P METHOD	SERUM

\*\* End Of Report \*\*

ENTERED BY

*Aswathy*  
MEDICAL BIOCHEMIST

MRS.ASWATHY.G.S

AUTHORIZED BY

Note: Lab tests have their limitations; results need not always correlate with clinical findings. But in the event any doubt: Please ask for a repetition with fresh specimen.

PRINTED TIME : 12/06/2024 09:38 AM

PRINTED BY : LIZY SK

OPD


Patient No	: 0001037018	Invoice No.	: 015271
Name	: MR.RAHUL OMANAKUTTAN	Invoice Date	: 11/06/2024 12:08:21 PM
Gender/ Age	: Male / 20 Yrs-5 Mths-30 Days	Sample Date	: 11/06/2024 01:10:07 PM
Sample #	: 12339941	Referred By	: Dr.SUKESH R S
Result Verified	: 11/06/2024 02:32:21 PM	Dept./Unit	: GENERAL MEDICINE

**LABORATORY REPORT  
SEROLOGY**


Test Name	Result	Ref. Range	Units	Method	Sample
HEPATITIS B SURFACE ANTIGEN	Non-Reactive			ECLIA	SERUM
HCV	Non-Reactive			ECLIA	SERUM

\*\* End Of Report \*\*

ENTERED BY



**CONSULTANT MICROBIOLOGIST**  
DR.ARCHANA SASIMOHAN  
MBBS,DNB(MICRO)MD(MICRO)  
AUTHORIZED BY



Note: Lab tests have their limitations; results need not always correlate with clinical findings. But in the event any doubt; Please ask for a repetition with fresh specimen.

PRINTED TIME : 12/06/2024 09:38 AM

PRINTED BY : LIZY SK


Patient No	: 0001037018	Invoice No.	: 015271
Name	: MR.RAHUL OMANAKUTTAN	Invoice Date	: 11/06/2024 12:08:21 PM
Gender/ Age	: Male / 20 Yrs-5 Mths-30 Days	Sample Date	: 11/06/2024 01:10:07 PM
Sample #	: 12339941	Referred By	: Dr.SUKESH R S
Result Verified	: 11/06/2024 02:32:21 PM	Dept./Unit	: GENERAL MEDICINE


LABORATORY REPORT  
CLINICAL PATHOLOGY

Test Name	Result	Ref. Range	Units	Method	Sample
<b>URINE ROUTINE ANALYSIS</b>					
COLOUR	amber				URINE
PH	5.000	4.400 - 6.200		REFLECTOMETRY	URINE
APPEARANCE	cloudy				URINE
SPECIFIC GRAVITY	1.025	1.001 - 1.030		CATION SENSITIVITY	URINE
ALBUMIN URINE	trace			REFLECTOMETRY	URINE
URINE SUGAR	neg			REFLECTOMETRY	URINE
ACETONE	neg			REFLECTOMETRY	URINE
BILE PIGMENTS	neg			REFLECTOMETRY	URINE
BILE SALTS	-				URINE
UROBILINOGEN	neg			REFLECTOMETRY	URINE
DEPOSITS[ MICROSCOPY]	-				URINE
PUS CELLS	2-3		/HPF	MICROSCOPY	URINE
EPITHELIAL CELLS	1-2		/HPF	MICROSCOPY	URINE
RBC	1-2	0-1	/HPF	MICROSCOPY	URINE
CRYSTALS	amorphous urates seen			MICROSCOPY	URINE
CAST	neg			MICROSCOPY	URINE
BACTERIA	neg			REFLECTOMETRY	URINE

\*\* End Of Report \*\*

BISMI.B  
ENTERED BY

  
DR.ILMA KUNJU MOHAMED  
MBBS,MD (PATHOLOGY)  
AUTHORIZED BY



Note: Lab tests have their limitations; results need not always correlate with clinical findings. But in the event any doubt, Please ask for a repetition with fresh specimen.

PRINTED TIME : 12/06/2024 09:38 AM

PRINTED BY : LIZY SK

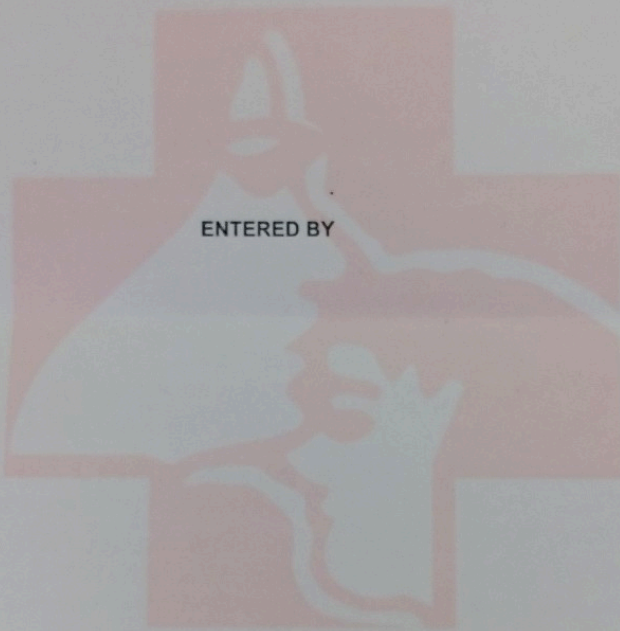
OPD

Patient No	: 0001037018	Invoice No.	: 015272
Name	: MR. RAHUL OMANAKUTTAN	Invoice Date	: 11/06/2024 12:09:24 PM
Gender/ Age	: Male / 20 Yrs-5 Mths-30 Days	Sample Date	: 11/06/2024 12:21:21 PM
Sample #	: 12339942	Referred By	: Dr. SUKESH R S
Result Verified	: 11/06/2024 04:03:50 PM	Dept./Unit	: GENERAL MEDICINE

LABORATORY REPORT  
 SEROLOGY

Test Name	Result	Ref. Range	Units	Method	Sample
HIV (ECLIA)	Non-Reactive			ECLIA	SERUM

\*\* End Of Report \*\*



ENTERED BY

*Archana*

CONSULTANT MICROBIOLOGIST

DR. ARCHANA SASIMOHAN  
 MBBS, DNB(MICRO) MD(MICRO)

AUTHORIZED BY

Note: Lab tests have their limitations; results need not always correlate with clinical findings. But in the event any doubt; Please ask for a repetition with fresh specimen.

PRINTED TIME : 11/06/2024 04:02 PM

PRINTED BY : ATHIRA.S.LEKHA



No. **295658**

**REPORT**

Patient ID:	1037018	Patient Name:	RAHUL OMANAKUTTAN 20Y/M
Age:	20	Sex:	M
Ref By:	DR.SUKESH	Study Date:	11-Jun-2024


**X-RAY CHEST (PA VIEW)**

**Observations:**

Lung fields do not show any focal abnormal radio density or lucency.  
Cardiac silhouette normal in configuration.  
Trachea and mediastinum normal in position.  
Right hilum appear normal.  
Left hilum appear normal.  
Both CP angles are clear. Normal position and contour diaphragm noted.  
Bony rib cage and soft tissue shadows appear normal.

**IMPRESSION:**

- No significant abnormalities in the present chest x-ray.

  
RADIOLOGIST  
ARYA G KRISHNAN  
MBBS, MD(Radio diagnosis)  
DNB (Radiodiagnosis)