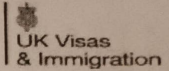


UK Pre-Departure Tuberculosis Detection Programme Medical Certificate



Certificate No : IND026N0057646

Issue Date : 06/06/2024

SP ID No : IND/026/N

Expiry Date : 05/12/2024

City /Town : MUMBAI

Country : INDIA

Given name(s) (as shown in passport) : BHAVYA MOHIT

Family name (as shown in passport) : SHAH

Gender : Male Female Date of Birth (DD/MM/YYYY) : 12/07/2003

Nationality : INDIAN Passport No : U 2560613

Number of accompanying children under 11 years of age : 0

Full residential address : 301, SHEETAL BUILDING CHSL, 191 AZAD ROAD, OPPOSITE KAMGAR KALYAN KENDRA, ANDHERI EAST, MUMBAI 400069

Address in the UK : Regents University London, Inner Circle, Regents Park, London, NW1 4NS, UK

Sputum Test : Not Done Negative

Chest X-Ray : Not Done Normal Abnormal

NO evidence of active pulmonary TB :

- Family contact with tuberculosis
- Pregnant
- Under 11 years of age undergone health assessment
- Chest X-Ray & interaction with applicant
- Referral letter given to applicant

IMPORTANT: You must carry this certificate with you, in your hand luggage, when you travel to the UK and present it to the immigration officer on arrival. Failure to do so will result in a delay to your journey as you may be required to undergo the tests again. Upon arrival in the UK you should register with a General Practitioner (GP) and supply a copy of this certificate for their records. If your X-ray shows abnormality requiring follow-up, we will also give a copy of the chest x-ray and x-ray interpretation and this should also be supplied.

SP Health Professional Name : DR. A. B. JAIN MBBS, PGD, CDM

Applicant's Signature : Bhavya M Shah

SP Health Professional Signature :

Date : 06/06/2024

Date : 06/06/2024

Visa Category : STUDENT VISA



The information contained within this document provides information in connection with your application for a United Kingdom visa ONLY and does not constitute a diagnosis or assurance of health for any other purpose. The issue of the certificate does not mean that your application for a visa will be successful.



Collection Date : 06/06/2024
Patient's Name : Mr.BHAVYA MOHIT SHAH

Print Date : 06/06/2024 Process Date : 06/06/2024
Sex : MALE Age : 20 Years
Lab No : 1124006204/ UKVI Ref No : U 2560613

XRAY REPORT
X-RAY CHEST P A VIEW

Both lung fields reveal normal translucency & bronchovascular markings.

Both the CP angles are clear.

The cardiac silhouette and the aorta are normal.

Both the hilar shadows are normal.

Both the domes of diaphragm are normal in contour & position.

Visualised dorsal spine and bony thorax appear normal.

Conclusion :

Normal chest skiagram.

* END OF REPORT *

Panel Radiologist

CDC SOUTH

A-2 Ben Nevis, Ground Floor
Bhulabhai Desai Road, Breach Candy
Mumbai 400-036

(022) 6119 6200 / 2368 4764 / 65
info.south@cdcgroupp.co.in

CDC NARIMAN POINT

Plot 1, Jagannath Bhosale Road
Near Mantralaya, Nariman Point
Mumbai 400-021

(022) 2286 6100
info.np@cdcgroupp.co.in

CDC NORTH

A-403 Floral Deck Plaza
'C' Cross Road, MIDC, Andheri (E)
Mumbai 400-093

(022) 6119 6300 6697 2352 / 53
info.north@cdcgroupp.co.in